

## MINI-SYMPOSIUM: EMERGING VIRAL INFECTIONS OF THE CENTRAL NERVOUS SYSTEM

**Henipavirus Encephalitis: Recent Developments and Advances**Kien Chai Ong<sup>1</sup>; Kum Thong Wong<sup>2</sup>Departments of <sup>1</sup>Biomedical Science and<sup>2</sup>Pathology, Faculty of Medicine, University of Malaya, Kuala Lumpur, Malaysia.**Keywords**

encephalitis, Hendra virus, Nipah virus, pathological.

**Corresponding author:**Kum Thong Wong, MBBS, MPATH, FRCPATH, MD, Department of Pathology, Faculty of Medicine, University of Malaya, 50603 Kuala Lumpur, Malaysia (E-mail: [wongkt@ummc.edu.my](mailto:wongkt@ummc.edu.my))

Received 13 June 2015

Accepted 18 June 2015

Conflict of interest: The authors declare no conflict of interest.

doi:10.1111/bpa.12278

**Abstract**

The genus *Henipavirus* within the family Paramyxoviridae includes the Hendra virus (HeV) and Nipah virus (NiV) which were discovered in the 1990s in Australia and Malaysia, respectively, after emerging to cause severe and often fatal outbreaks in humans and animals. While HeV is confined to Australia, more recent NiV outbreaks have been reported in Bangladesh, India and the Philippines. The clinical manifestations of both henipaviruses in humans appear similar, with a predominance of an acute encephalitic syndrome. Likewise, the pathological features are similar and characterized by disseminated, multi-organ vasculopathy comprising endothelial infection/ulceration, vasculitis, vasculitis-induced thrombosis/occlusion, parenchymal ischemia/microinfarction, and parenchymal cell infection in the central nervous system (CNS), lung, kidney and other major organs. This unique dual pathogenetic mechanism of vasculitis-induced microinfarction and neuronal infection causes severe tissue damage in the CNS. Both viruses can also cause relapsing encephalitis months and years after the acute infection. Many animal models studied to date have largely confirmed the pathology of henipavirus infection, and provided the means to test new therapeutic agents and vaccines. As the bat is the natural host of henipaviruses and has worldwide distribution, spillover events into human populations are expected to occur in the future.

**INTRODUCTION**

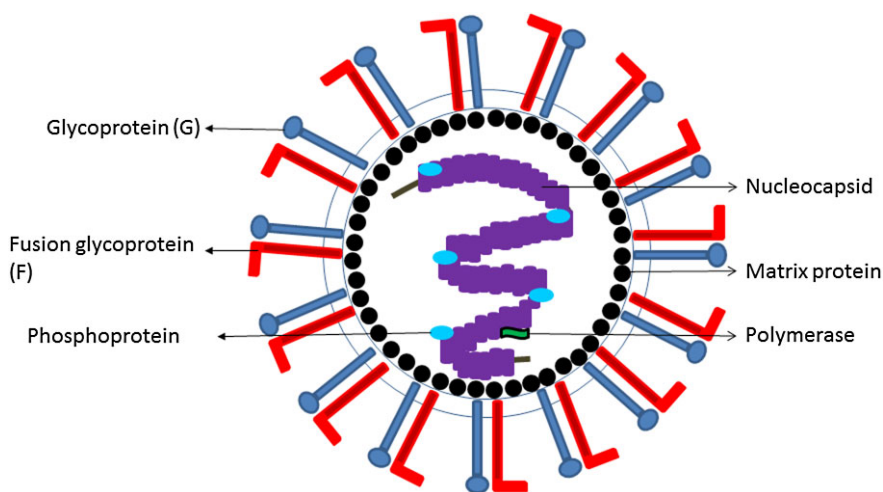
The *Henipavirus* genus in the subfamily Paramyxovirinae (family Paramyxoviridae) that also includes the well-known measles virus (genus: *Morbillivirus*) was originally created for two pathogenic viruses, Hendra and Nipah (123). Since then, nonpathogenic Cedar virus has also been included into *Henipavirus* (71). More recently, many newly discovered African henipaviruses and a pathogenic henipavirus from the Philippines have been reported, all of which have not been isolated or fully characterized (14, 27). Hendra virus (HeV) and Nipah virus (NiV) are enveloped, pleomorphic virions with diameters averaging about 500 nm, but may range from about 40 to 1900 nm in length (38, 55). Each virion contains a tangle of nucleocapsids with a herringbone structure typical of paramyxoviruses. As negative-sense, single-stranded RNA viruses, they have unusually large genomes of more than 18 000 nucleotides, comprising six genes encoding for the nucleocapsid, phosphoprotein, matrix protein, fusion glycoprotein (F), attachment glycoprotein (G) and the large polymerase (Figure 1). The viral G protein attaches to the host cell ephrin B2 and/or B3 receptor, and activates the F protein to initiate viral envelop and host membrane fusion and viral entry (4, 82, 91).

Various aspects of HeV and NiV infections, including pathology and pathogenesis, have been reviewed previously, either

individually or as henipaviruses (69, 116, 129, 130, 133, 135, 137). The purpose of this review is to revisit what is currently known and to describe recent developments and advances of emerging henipaviruses as deadly zoonotic infections with human outbreaks continue to be reported in Bangladesh and the Philippines (14, 98).

HeV was first isolated in 1994, five years before NiV, after an outbreak in horses and two humans in Australia, hence its original name, Equine Morbillivirus (81, 109). To date, numerous outbreaks in horses and a total of seven human infections with four fatalities have been reported (47, 69, 85, 92). So far, no HeV cases have been reported outside Australia.

NiV was first isolated in 1999 after outbreaks in pigs and humans in Malaysia and Singapore from 1998 to 1999 (12, 19). Although not precisely known, the number of infected pigs must have been at least in the hundreds. It was estimated that there were more than 350 human cases, both asymptomatic and symptomatic (135), including at least 265 cases of acute NiV encephalitis with 105 fatalities (88, 89). From 2001 onwards, several recurrent outbreaks of NiV in Bangladesh and an outbreak in the adjacent Indian state of West Bengal have probably involved more than 250 people with a fatality rate of about 70% (49, 57, 68). The latest outbreak of nine cases in Bangladesh was reported in early 2015 (98), and a henipavirus outbreak involving 17 people, more likely due to NiV, occurred in the Philippines in 2014 (14).



**Figure 1.** Diagrammatic representation of the henipavirus virion with an outer, plasma membrane-derived envelop through which the viral G and F glycoproteins protrude. The matrix protein is found under the envelop. The central core consists of the nucleocapsid, viral RNA, phosphoprotein and polymerase.

## NATURAL HOSTS AND HENIPAVIRUS TRANSMISSION TO HUMANS

The natural host of henipaviruses has been confirmed to be bats. HeV has been isolated from *Pteropus alecto* and a few other *Pteropus* species (flying foxes) found in Australia (111). NiV was isolated from *P. hypomelanus* and *P. vampyrus* (Malaysia), and *P. lylei* (Cambodia), and NiV RNA recovered from *P. giganteus* (India), *P. vampyrus* (Indonesia) and *P. lylei* (Thailand) (29, 100, 110, 120). Viral RNAs of African henipaviruses have been detected in various species of non-pteropid bats, including *Eidolon helvum* (27). Zoonotic henipavirus transmission to humans can occur in several ways: (i) direct bat-to-human transmission; (ii) bat-to-intermediate host-to-human transmission; and (iii) human-to-human transmission. The best example of bat-to-human transmission was from Bangladesh where humans became infected when they drank raw date palm sap contaminated by NiV-infected bats that had fed at overnight collection pots (67).

For both NiV and HeV, involvement of intermediate hosts is common. Most likely urine and oronasal secretions from infected animals were responsible for passing the infection to humans through direct or possibly airborne exposure (75, 92, 109). In the NiV outbreak in Malaysia and Singapore, the pig was the main intermediate host, and pig farmers, abattoir workers, pork sellers and army personnel involved with culling of pigs had the highest prevalence of infection (2, 13, 88, 95, 106). Bat-to-pig transmission could have resulted from pigs consuming half-eaten, contaminated fruits dropped by bats (20). Other domestic animals such as dogs, cows and goats may have the potential to act as intermediate hosts for NiV (18, 76, 133). Human HeV outbreaks were closely associated with infection in horses and indeed occurred mainly among veterinarians, stable workers and other personnel in close contact with horses. Though rare, the HeV-infected dog may also have the potential to be an intermediate host (97). Bat-to-horse transmission remains unclear but is likely to be due to environmental contamination from bat urine or other bat-derived materials (31, 127). Interestingly, in the henipavirus outbreak in the Philippines, the majority of patients were involved with slaughtering infected horses and/or consuming under-cooked horse meat (14).

Human-to-human transmission was firmly established in the NiV outbreaks in Bangladesh and India where a relatively high incidence was reported either in family members or other people in contact with patients, and in health care workers (44, 49, 54). Although human-to-human transmission may well have occurred in the Malaysia/Singapore outbreaks, the only well-documented case was in a nurse who seroconverted but remained asymptomatic despite brain magnetic resonance imaging (MRI) that showed a few typical lesions of acute encephalitis (115, 117). In other health staff involved with patient care, serum neutralization tests were found to be negative, possibly because of good clinical prophylactic measures (78). In the Philippines' henipavirus outbreak, the clinical and epidemiological evidence also suggested human-to-human transmission (14). To date, bat-to-human or human-to-human HeV transmission has not been reported (69). It is perhaps not surprising that human-to-human henipavirus transmission can occur as virus has been detected in various excretions from patients (21, 92).

## CLINICAL MANIFESTATIONS AND SEQUELAE

The incubation period of henipavirus infections ranges from a few days to about 3 weeks. Milder clinical features include fever, nonspecific influenza-like illness, lethargy, myalgia and headache (14, 16, 37, 92, 109). In general, the more severe clinical features manifest as either an acute encephalitic syndrome or less frequently a pulmonary syndrome. It is also very likely that there is a considerable number of infections that remained asymptomatic but the exact prevalence is unknown.

As there have been only seven known cases of human HeV infection, much less is known about its clinical manifestations compared with NiV infection. Nonetheless, the acute encephalitic syndrome is characterized by drowsiness, confusion, ataxia, ptosis and seizures. One patient had a pulmonary syndrome described as a pneumonitis with chest radiograph findings of diffuse alveolar shadowing (69, 92, 109). However, at autopsy, this patient's brain also showed features of acute encephalitis that had not been

clinically apparent (134). Two clinical encephalitis cases also had similar abnormal chest radiographs.

Severe NiV infection appears to be more frequently manifested as an acute encephalitic syndrome. In the largest cohort of 90 patients with acute NiV encephalitis admitted to a single hospital, apart from the symptoms seen in milder infections, 53% of patients had reduced consciousness (37). Clinical signs such as areflexia/hyporeflexia with hypotonia, pinpoint pupils with variable reactivity, tachycardia, hypertension and abnormal doll's eye reflex were more frequently seen in patients with reduced level of consciousness. Segmental myoclonus characterized by focal, rhythmic jerking of the diaphragm and muscles in the limbs, neck and face was present in 30% of patients, and may be unique to acute NiV encephalitis. Other clinical features (eg, meningism, generalized tonic-clonic convulsions, nystagmus and cerebellar signs) were also observed. Similar findings were also found in patient cohorts from Bangladesh and Singapore (53, 61). In Bangladesh, altered mental status and/or unconsciousness was reported in >70%, severe weakness in 67% and areflexia/hyporeflexia in 65% of cases, consistent with a high prevalence of acute encephalitis. In the Philippines' henipavirus outbreak, 11 of 17 cases (65%) were reported to have acute encephalitis and 1 case had meningitis but no encephalitis (14).

Generally, brain MRI scans were useful for diagnosis of acute henipavirus encephalitis showing multiple, disseminated, small discrete hyperintense lesions mainly in the cerebral cortex, subcortical and deep white matter (65, 69, 92, 107). In addition to this, acute HeV encephalitis lesions may be larger and more confluent, similar to some acute NiV encephalitis cases in Bangladesh (99).

Overall, mortality is high in henipavirus infections ranging from about 40% to 70% (49, 53, 69, 88). In a large cohort of patients who survived, the majority had no or few sequelae (37). Some patients were reported to have neurological deficits, neuropsychiatric sequelae and gait/movement disorders (83, 108). Fatal intracerebral hemorrhage is a very rare complication (37). The most interesting complication is probably relapsing encephalitis which may occur weeks to years after symptomatic henipavirus infection (mild, non-encephalitis illness or acute encephalitis) and even after asymptomatic NiV infection/seroconversion (85, 108, 114). So far, there has been only 1 case of relapsing HeV encephalitis and >20 cases of relapsing NiV encephalitis (possibly involving <10% of survivors), one of which occurred 11 years after an asymptomatic infection (1). Clinical and radiological findings suggest that relapsing NiV encephalitis is distinct from acute NiV encephalitis (107, 114). The brain MRI in relapsing henipavirus encephalitis shows more extensive and confluent hyperintense cortical lesions. Virus could not be cultured from cerebrospinal fluid, naso-tracheal secretions, urine and brain tissue in a series of NiV relapsing encephalitis (114).

## LABORATORY DIAGNOSIS

Detection of anti-henipavirus antibodies remains a key to establishing the diagnosis both in animals and humans because the diagnosis may not be suspected initially, and disease manifestations can be rather nonspecific. Enzyme-linked immunosorbent assays (ELISA) that were developed during the initial HeV and NiV outbreaks in Australia and Malaysia, respectively, proved to

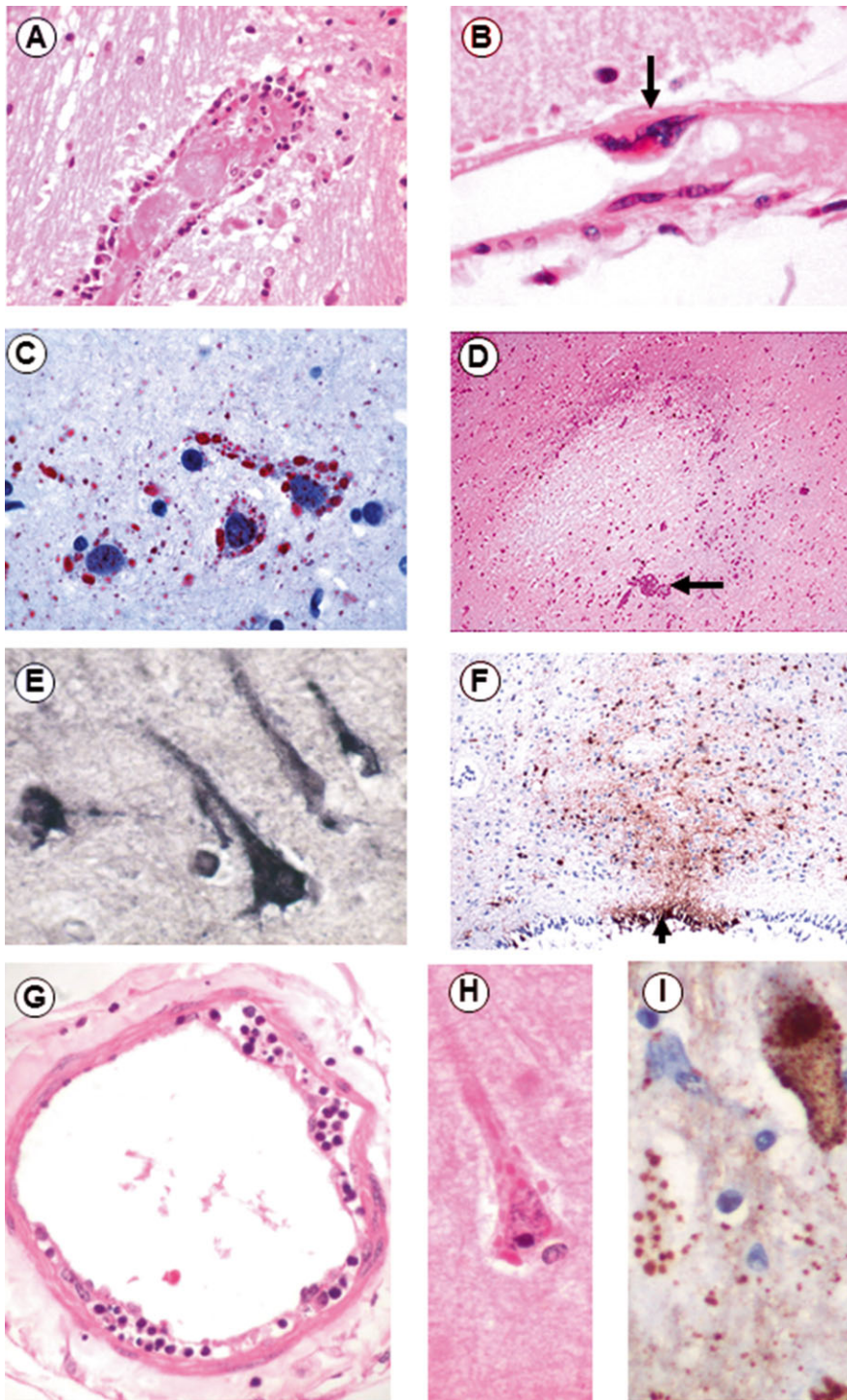
be very useful as a screening test and were widely applied to diagnose these infections in animals and humans (122). Subsequently in Bangladesh, the first NiV outbreaks were only suspected after these tests were found to be positive in patients (54). In human NiV infection, IgM seroconversion from day 4 to day 12 was about 65%–100%, persisting for at least 3 months, while IgG seroconversion by day 25 was 100% and persisted for several years (17, 101). These tests have also been used widely for investigative field studies in bats and other animals (56, 58, 120). Specific IgM or IgG has also been reported in HeV-infected patients (47, 85, 109).

Serum neutralization tests, although accepted as the reference standard to confirm henipavirus infection, may not be done in most laboratories because this test involves handling live viruses which requires biosafety level 4 facilities. An innovative pseudotyped vesicular stomatitis virus bearing the NiV F and G proteins has been used to obviate this requirement, and was shown to be more sensitive than conventional serum neutralization tests, and applicable for both HeV and NiV infections (14, 59, 113). Specific and reliable PCR-based methods and sequencing (30, 42, 122) to identify henipaviruses are now more widely available for outbreak investigations and diagnosis, and have begun to replace serological testing (51, 111, 140). Where infected animal or human tissues are available, immunohistochemistry using specific anti-henipavirus antibodies is useful to confirm the diagnosis (34, 130, 133).

## PATHOLOGY OF HUMAN HENIPAVIRUS INFECTION

The pathology of acute HeV and NiV infections appears to be similar although our current knowledge of acute henipavirus infection is based on only 3 autopsies of HeV infection, and >30 autopsies of NiV infection (69, 134, 136). Acute henipavirus infection is characterized by disseminated small vessel vasculopathy comprising endothelial infection/ulceration, vasculitis (Figure 2A,G) and vasculitis-induced thrombosis/occlusion (Figure 2A), often resulting in parenchymal ischemia and microinfarction in the central nervous system (CNS) (Figure 2D), lung, kidney and other major organs (134, 136). In about 25% of NiV infections, endothelial multinucleated syncytia have been detected (Figure 2B). This feature is probably unique to henipavirus infection as it has not been described in other infections, including measles. Viral antigens/RNA and nucleocapsids were detectable in vascular endothelium, multinucleated giant cells and smooth muscle.

Vasculopathy was most severe in the CNS and frequently associated with discrete necrotic or more subtle vacuolar, plaque-like lesions (Figure 2D,F). As neuronal viral inclusions/antigens/RNA were often demonstrable (Figure 2C,E,F,H,I), the lesions were probably the result of microinfarction and/or neuronal infection. Similar white matter necrotic lesions were probably pure microinfarcts as glial cells were far less susceptible to infection. Focal neuronophagia, microglial nodule formation, clusters of foamy macrophages, perivascular cuffing and meningitis can also be found but extravascular paramyxoviral Warthin–Finkeldey multinucleated giant cells were absent. The dual pathogenic mechanisms of vasculopathy and parenchymal cell infection in multiple organs may be unique to acute henipavirus infection (136).



**Figure 2.** Pathology of henipavirus infection: vasculopathy in Nipah virus encephalitis showing vasculitis, thrombosis (A) and endothelial multinucleated syncytia with viral inclusion (B, arrow). There are numerous Nipah viral inclusions/antigens within neurons (C), especially around necrotic plaques (D). Necrotic plaques may also have evidence of adjacent vascular thrombo-occlusion (D, arrow). Vasculitis in Hendra encephalitis may manifest as mild endothelitis (G). Hendra viral inclusions (H), antigens (F,I) and RNA (E) can be demonstrated in neurons. Viral antigens may also localize to the ependyma (F, arrow). Hematoxylin and eosin stain (A,B,D,G, H). Immunohistochemistry with new fuchsin (C) and DAB (F,I) chromogens, hematoxylin counterstain. *In situ* hybridization with NBT/BCIP substrate, and hematoxylin counterstain. Original magnification: x40 (A-I). Permissions were obtained from reference 133 for A and B; reference 136 for C and D; reference 134 for E-I.

The pathological features of relapsing henipavirus encephalitis were based on an autopsy case of HeV (134) and autopsies of relapsing NiV encephalitis (114, 136). Relapsing HeV and NiV encephalitides are similar where pathology was confined to the CNS. Confluent and extensive parenchymal necrosis, edema and inflammation were seen mainly in neuronal areas where there was prominent perivascular cuffing, severe neuronal loss, reactive

gliosis and neovascularization. Focal viral inclusions/antigens/RNA and nucleocapsids were demonstrated mainly in surviving neurons. Severe meningitis was found in many areas. Notably, vasculitis, endothelial syncytia and thrombosis seen in acute henipavirus encephalitis were absent and blood vessels were all negative for antigens/RNA. The presence of viral inclusions, nucleocapsids, antigens and RNA confirmed relapsing henipavirus

encephalitis as a recurrent infection rather than postinfectious encephalitis (114). The absence of vasculopathy and extra-CNS organ involvement suggests reactivation of latent viral foci within the CNS rather than virus reentry from an extra-CNS site.

The risk factors for relapsing henipavirus encephalitis are unknown. Clinically and pathologically, relapsing henipavirus encephalitis appears to share some similarities with subacute sclerosing panencephalitis (SSPE). Moreover, like relapsing henipavirus encephalitis, SSPE is not invariably fatal and recurrences have been reported (17, 26, 114). Similar measles virus mutations associated with SSPE (11) have so far not been reported in relapsing NiV encephalitis (131). Measles virus is known to cause immune suppression (39), and being paramyxoviruses, henipaviruses could possibly cause immune suppression leading to relapsing encephalitis.

## **PATHOLOGY OF ACUTE HENIPAVIRUS INFECTION IN ANIMALS**

Animal studies have contributed to our understanding of henipavirus pathology and pathogenesis (23, 34, 75, 126, 133). Many mammalian species can be infected either under natural or experimental conditions. The range of susceptible includes the definitive host (bat), known intermediate hosts (horse, pig, dog) and other experimental animal models (mouse, hamster, cat, guinea pig, ferret, chicken embryo, African green monkey and squirrel monkey) (7, 33, 43, 52, 63, 70, 73, 74, 104, 119, 127, 128, 132). Overall, the findings in animals have confirmed the findings in human autopsies that the acute infection is a disseminated, multi-organ disease characterized by vasculopathy and parenchymal cell infection. This extensive dual pathogenic mechanism of tissue injury is responsible for the severity and high mortality of henipavirus infection.

The bat as the definitive and reservoir host for henipaviruses demonstrated little evidence of pathology except for focal mild vasculitis (126). Perhaps the hamster and the African green monkey may be the best known animal models for both NiV and HeV because the pathological findings appear to most accurately recapitulate changes in humans, in particular CNS vasculopathy and neuronal infection. Although vasculopathy was invariably present, neuronal infection and encephalitis were not prominent in the ferret, pig, cat, horse and guinea pig (except in high HeV doses) models. NiV infection in mice was subclinical (28), but older mice were susceptible to HeV for reasons possibly related to interferon I response after viral entry (25) or perhaps to other host responses such as CXCL10, a chemokine induced by NiV (72). An interesting but rare finding was neuronal syncytia formation in the hamster and chicken embryo CNS (118, 133). In addition to vasculopathy and lung parenchyma infection seen in most animal models, the pig also showed prominent infection and syncytia formation in the bronchial epithelium (63, 133). The dog has not been studied as model for henipavirus infection but naturally infected animals have some similarity to human pathology (52, 133).

Apart from the obvious hematogenous spread into the CNS via damaged blood vessel/blood-brain barrier, recent animal studies in pig, mouse and hamster models have demonstrated neuroinvasion via infected nasal mucosa, and then into the olfactory bulb to enter the CNS (28, 80, 124). So far, there has been no

direct evidence for this in human infection (136). Despite NiV strains from Bangladesh and Malaysia sharing about 91.8% genomic sequence homology (48), the infectious disease pathology may still differ. To address this question, two separate studies using the hamster model were performed. In one study, the Malaysian strain caused a more accelerated infection (24), but in another study there were no apparent significant differences (3). A study in ferrets also showed no pathological differences except for higher viral titers in oral secretions following infection with the Malaysian strain (22). Further studies by manipulating NiV genome using a recently described infectious clone may be helpful to further understand the differences, if any, between Bangladesh and Malaysian strains (142). The only study so far that directly compared HeV and NiV infections in an animal model (hamster) did not appear to demonstrate significant differences in the two viruses either, except for the finding that NiV initially replicated in the upper respiratory tract epithelium, whereas early HeV replication was in lung interstitium (105).

## **THERAPEUTIC AND VACCINE DEVELOPMENT**

To date, there are no approved vaccines or therapeutic agents to treat human henipavirus infection. Various approaches being pursued as part of ongoing research have been reviewed (8). During the NiV outbreak in Malaysia, ribavirin (a broad spectrum antiviral drug) was given empirically, and subsequently thought to be useful for patients (15). However, its effect on human HeV infections, if any, was uncertain (69). Nonetheless, as it was found to have some effect on henipaviruses experimentally (36, 139), ribavirin was further tested for its anti-henipavirus properties either alone or in combination with a potentially useful antimalarial drug called chloroquine (94). Unfortunately, in the hamster, ferret and African green monkey models, ribavirin or ribavirin/chloroquine combinations were found to be ineffective against infection and disease (32, 86, 104). Other drugs have been suggested as having possible anti-henipavirus effects (69).

Passive immunization strategies using cross reacting, henipavirus-specific antibodies raised against F and G viral proteins have been investigated in hamster, ferret and African green monkey models and found to be effective (5, 7, 35, 40, 41, 43). In fact, on humanitarian grounds, two patients with HeV infection have been given these antibodies with no adverse effects but the antiviral effectiveness has not been verified (9). Many new vaccine candidates for active immunization using different live recombinant vaccine, subunit vaccine and virus-like particle platforms that mainly express henipavirus F and/or G proteins have been successfully developed and tested in various animal models including hamsters, pigs, cats, ferrets and African green monkeys models (6, 40, 60, 66, 77, 79, 87, 93, 96, 121, 125, 141). One of the recombinant subunit vaccines that contained the HeV G glycoprotein has now been licensed for use by the equine industry in Australia (103).

## **CONCLUSION**

As far as newly emerging viruses, including henipaviruses, Ebola virus, SARS coronavirus, are concerned, one of the most important natural hosts is the bat (10, 112, 138). Because of the

worldwide distribution and their flying range that can cover huge areas of human habitat in Southeast Asia, China, Japan, Oceania, Indian subcontinent, Australia and Africa, pteropid bats, in particular, are highly effective in virus dissemination (20, 29, 45, 46, 50, 54, 62, 64, 84, 102, 120). Hence, future henipavirus outbreaks in new areas/countries are probably inevitable as shown by the recent outbreak in the Philippines (14). A group of Africans who were involved with butchering bats for bush meat was recently found to be seropositive, thus providing evidence of previously unknown henipavirus spillover events in a continent that has yet to witness a henipavirus outbreak (90). The concept of One Health that integrates activities and contributions of international scientists, ecologists, veterinarians, health professionals, politicians and other stakeholders may be needed to minimize future outbreaks of bat-borne zoonoses (112).

## ACKNOWLEDGMENTS

This study was supported in part by the University of Malaya/Ministry of Education High Impact Research Grant (H-20001-00-E000004).

## REFERENCES

- Abdullah S, Chang LY, Rahmat K, Goh KJ, Tan CT (2012) Late-onset Nipah virus encephalitis 11 years after the initial outbreak: a case report. *Neurol Asia* **17**:71–74.
- Ali R, Mounts AW, Parashar UD, Sahani M, Lye MS, Isa MM *et al* (2001) Nipah virus among military personnel involved in pig culling during an outbreak of encephalitis in Malaysia, 1998–1999. *Emerg Infect Dis* **7**:759–761.
- Baseler L, de Wit E, Scott D, Munster VJ, Feldman H (2015) Syrian hamsters (*Mesocricetus auratus*) oronasally inoculated with Nipah virus isolate from Bangladesh or Malaysia develop similar respiratory tract lesions. *Vet Pathol* **52**:38–45.
- Bonaparte MI, Dimitrov AS, Bossart KN, Crameri G, Mungall BA, Bishop KA *et al* (2005) Ephrin-B2 is a functional receptor for Hendra virus and Nipah virus. *Proc Natl Acad Sci U S A* **102**:10652–10657.
- Bossart KN, Geisbert TW, Feldman H, Zhu Z, Feldmann F, Geisbert JB *et al* (2011) A neutralizing human monoclonal antibody protects African green monkeys from Hendra virus challenge. *Sci Transl Med* **3**:105ra3.
- Bossart KN, Rockx B, Feldmann F, Brining D, Scott D, LaCasse R *et al* (2012) A Hendra virus G glycoprotein subunit vaccine protects African green monkeys from Nipah virus challenge. *Sci Transl Med* **4**:146ra07.
- Bossart KN, Zhu Z, Middleton D, Klippel J, Crameri G, Bingham J *et al* (2009) A neutralizing human monoclonal antibody protects against lethal disease in a few ferret model of acute Nipah virus infection. *PLoS Pathog* **5**:e1000642.
- Broder CC, Geisbert TW, Xu K, Nikolov DB, Wang LF, Middleton D *et al* (2012) Immunization strategies against henipaviruses. *Curr Top Microbiol Immunol* **359**:197–223.
- Broder CC, Xu K, Nikolov DB, Zhu Z, Dimitrov DS, Middleton D *et al* (2013) A treatment for and vaccine against the deadly Hendra and Nipah viruses. *Antiviral Res* **100**:8–13.
- Calisher CH, Childs JE, Field HE, Holmes KV, Schountz T (2006) Bats: important reservoir hosts of emerging viruses. *Clin Microbiol Rev* **19**:531–545.
- Cattaneo R, Schmid A, Spielhofer P, Kaelin K, Bacsko K, ter Meulen V *et al* (1989) Mutated and hypermutated genes of persistent measles viruses which caused lethal human brain diseases. *Virology* **173**:415–425.
- CDC (1999) Update: outbreak of Nipah virus—Malaysia and Singapore, 1999. *MMWR Morb Mortal Wkly Rep* **48**:335–337.
- Chew MH, Arguin PM, Shay DK, Goh KT, Rollin PE, Shieh WJ *et al* (2000) Risk factors for Nipah virus infection among abattoir workers in Singapore. *J Infect Dis* **181**:1760–1763.
- Ching PKG, de los Reyes VC, Sualdito MN, Tayag E, Columna-Vingno AB, Malbas FF Jr *et al* (2015) Outbreak of henipavirus infection, Philippines, 2014. *Emerg Infect Dis* **21**:328–331.
- Chong HT, Kamarulzaman A, Tan CT, Goh KJ, Thayaparan T, Kunjapan SR *et al* (2001) Treatment of acute Nipah encephalitis with Ribavirin. *Ann Neurol* **49**:810–813.
- Chong HT, Kunjapan SR, Thayaparan T, Tong JMG, Petharunam V, Jusoh MR, Tan CT (2000) Nipah encephalitis outbreak in Malaysia, clinical features in patients from Seremban. *Neurol J Southeast Asia* **5**:61–67.
- Chong HT, Tan CT (2003) Relapsed and late-onset Nipah encephalitis, a report of three cases. *Neurol J Southeast Asia* **8**:109–112.
- Chowdhury S, Khan SU, Crameri G, Epstein JH, Broder CC, Islam A *et al* (2014) Serological evidence of henipavirus exposure in cattle, goats and pigs in Bangladesh. *PLoS Negl Trop Dis* **8**:e3302.
- Chua KB, Bellini WJ, Rota PA, Harcourt BH, Tamin A, Lam SK *et al* (2000) Nipah virus: a recently emergent deadly paramyxovirus. *Science* **288**:1432–1435.
- Chua KB, Koh CL, Hooi PS, Wee KF, Khong JH, Chua BH *et al* (2002) Isolation of Nipah virus from Malaysian island flying-foxes. *Microbes Infect* **4**:145–151.
- Chua KB, Lam SK, Goh KJ, Hooi PS, Ksiazek T, Kamarulzaman A *et al* (2001) The presence of Nipah virus in respiratory secretions and urine of patients during an outbreak of Nipah virus encephalitis in Malaysia. *J Infect* **42**:40–43.
- Clayton BA, Middleton D, Bergfeld J, Haining J, Arkininstall R, Wang LF, Marsh GA (2012) Transmission routes for Nipah virus from Malaysia and Bangladesh. *Emerg Infect Dis* **18**:1983–1993.
- de Wit E, Munster VJ (2015) Animal models of disease shed light on Nipah virus pathogenesis and transmission. *J Pathol* **235**:196–205.
- DeBuysscher BL, de Wit E, Munster VJ, Scott D, Feldmann H, Prescott J (2013) Comparison of the pathogenicity of Nipah virus Isolates from Bangladesh and Malaysia in the Syrian hamster. *PLoS Negl Trop Dis* **7**:e2024.
- Dhondt KP, Mathieu C, Chalons M, Reynaud JM, Vallve A, Raoul H, Horvat B (2012) Type I Interferon signaling protects mice from lethal henipavirus infection. *J Infect Dis* **207**:142–151.
- Donner M, Waltimo J, Porras J, Forsius H, Saukkonen AL (1972) Subacute sclerosing panencephalitis as a cause of chronic dementia and relapsing brain disorder. *J Neurol Neurosurg Psychiatry* **35**:180–185.
- Drexler JF, Corman VM, Müller MA, Maganga DG, Vallo P, Binger T *et al* (2012) Bats host major mammalian paramyxoviruses. *Nat Commun* **3**:796. doi: 10.1038/ncomms1796 (2012).
- Dups J, Middleton D, Yamada M, Monaghan P, Long F, Robinson R *et al* (2012) A new model for Hendra virus encephalitis in the mouse. *PLoS ONE* **7**:e40308.
- Epstein JH, Prakash V, Smith CS, Daszak P, McLaughlin AB, Meehan G *et al* (2008) Henipavirus infection in fruit bats (*Pteropus giganteus*), India. *Emerg Infect Dis* **14**:1309–1311.
- Feldman KS, Foord AJ, Heine HG, Smith IL, Boyd V, Marsch GA *et al* (2009) Design and evaluation of consensus PCR assays for henipaviruses. *J Virol Methods* **161**:52–57.

31. Fogarty R, Halpin K, Hyatt AD, Saszak P, Mungall BA (2008) Henipavirus susceptibility to environmental variables. *Virus Res* **132**:140–144.
32. Freiberg AN, Worthy MN, Lee B, Holbrook MR (2010) Combined chloroquine and ribavirin treatment does not prevent death in a hamster model of Nipah and Hendra virus infection. *J Gen Virol* **91**:765–772.
33. Geisbert TW, Daddario-Dicaprio KM, Hickey AC, Smith MA, Chan YP, Wang LF *et al* (2010) Development of an acute and highly pathogenic nonhuman primate model of Nipah virus infection. *PLoS ONE* **5**:e10690.
34. Geisbert TW, Feldman H, Broder CC (2012) Animal challenge models of henipavirus infection and pathogenesis. *Curr Top Microbiol Immunol* **359**:153–177.
35. Geisbert TW, Mire CE, Geisbert JB, Chan YP, Agans KN, Feldmann F *et al* (2014) Therapeutic treatment of Nipah virus infection in nonhuman primates with a neutralizing human monoclonal antibody. *Sci Transl Med* **6**:242ra82.
36. Georges-Courbot MC, Contamin H, Faure C, Loth P, Baize S, Leyssen P *et al* (2006) Poly(I)-poly(C12U) but not ribavirin prevents death in a hamster model of Nipah infection. *Antimicrob Agents Chemother* **50**:1768–1772.
37. Goh KJ, Tan CT, Chew NK, Tan PSK, Kamarulzaman A, Sarji SA *et al* (2000) Clinical features of Nipah virus encephalitis among pig farmers in Malaysia. *N Engl J Med* **342**:1229–1235.
38. Goldsmith CS, Whistler T, Rollin PE, Ksiazek TG, Rota PA, Bellini WJ *et al* (2002) Elucidation of Nipah virus morphogenesis and replication using ultrastructural and molecular approaches. *Virus Res* **92**:89–98.
39. Griffin DE, Bellini WJ (1996) Measles virus. In: *Field's Virology*. B Fields, D Knipe, P Howley, R Chanock, J Melnick, T Monath *et al* (eds), pp. 1267–1312. Lippincott-Raven: Philadelphia.
40. Guillaume V, Contamin H, Loth P, Georges-Courbot MC, Lefeuvre A, Marianneau P *et al* (2004) Nipah virus: vaccination and passive protection studies in a hamster model. *J Virol* **78**:834–840.
41. Guillaume V, Contamin H, Loth P, Grosjean I, Georges-Courbot MC, Deubel V *et al* (2006) Antibody prophylaxis and therapy against Nipah virus infection in hamsters. *J Virol* **80**:1972–1978.
42. Guillaume V, Lefeuvre A, Faure C, Marianneau P, Buckland R, Lam SK *et al* (2004) Specific detection of Nipah virus using real-time RT-PCR (TaqMan). *J Virol Methods* **120**:229–237.
43. Guillaume V, Wong KT, Looi RY, Georges-Courbot MC, Barrot L, Buckland R *et al* (2009) Acute Hendra virus infection: analysis of the pathogenesis and passive antibody protection in the hamster model. *Virology* **387**:459–465.
44. Gurley ES, Montgomery JM, Hossain MJ, Bell M, Azad AK, Islam MR *et al* (2007) Person-to-person transmission of Nipah virus in a Bangladeshi community. *Emerg Infect Dis* **13**:1031–1037.
45. Halpin K, Young PL, Field H, Mackenzie JS (1999) Newly discovered viruses of flying foxes. *Vet Microbiol* **68**:83–87.
46. Halpin K, Young PL, Field HE, Mackenzie JS (2000) Isolation of Hendra virus from pteropid bats: a natural reservoir of Hendra virus. *J Gen Virol* **81**:1927–1932.
47. Hanna JN, McBride WJ, Brookes DL, Shield J, Taylor CT, Smith IL *et al* (2006) Hendra virus infection in a veterinarian. *Med J Aust* **185**:562–564.
48. Harcourt BH, Lowe L, Tamin A, Liu X, Bankamp B, Bowden N *et al* (2005) Genetic characterization of Nipah virus, Bangladesh, 2004. *Emerg Infect Dis* **11**:1594–1597.
49. Harit AK, Ichhpujani RL, Gupta S, Gill KS, Lal S, Ganguly NK, Agarwal SP (2006) Nipah/Hendra virus outbreak in Siliguri, West Bengal, India in 2001. *Indian J Med Res* **123**:553–560.
50. Hayman DTS, Suu-Ire R, Breed AC, McEachern JA, Wang L, Wood JLN, Cunningham AA (2008) Evidence of Henipavirus infection in West African fruit bats. *PLoS ONE* **3**:e2739.
51. Hess IMR, Massey PD, Walker B, Middleton DJ, Wright TM (2011) Hendra virus: what do we know? *N S W Public Health Bull* **22**:118–122.
52. Hooper P, Zaki S, Daniels P, Middleton D (2001) Comparative pathology of the diseases caused by Hendra and Nipah viruses. *Microbes Infect* **3**:315–322.
53. Hossain MJ, Gurley ES, Montgomery JM, Bell M, Carroll DS, Hsu VP *et al* (2008) Clinical presentation of Nipah virus infection in Bangladesh. *Clin Infect Dis* **46**:977–984.
54. Hsu VP, Hossain MJ, Parashar UD, Ali MM, Ksiazek TG, Kuzmin I *et al* (2004) Nipah virus encephalitis emergence, Bangladesh. *Emerg Infect Dis* **10**:2082–2087.
55. Hyatt A, Zaki SR, Goldsmith CS, Wise TG, Hengstberger SG (2001) Ultrastructure of Hendra virus and Nipah virus within cultured cells and host animals. *Microbes Infect* **3**:297–306.
56. Lehle C, Razafitrimo G, Razainirina J, Andriaholinirina N, Goodman SM, Faure C *et al* (2007) Henipavirus and Tioman virus antibodies in pteropodid bats, Madagascar. *Emerg Infect Dis* **13**:159–161.
57. Institute of Epidemiology Disease Control and Research Nipah Virus Outbreak. Available at: <http://www.iedc.org/>.
58. Johara MY, Field H, Rashdi AM, Morissy C, van der Heide B, Rota P *et al* (2001) Nipah virus infection in bats (Order Chiroptera) in Peninsular Malaysia. *Emerg Infect Dis* **7**:439–441.
59. Kaku Y, Noguchi A, Marsh GA, Barr JA, Okutani A, Hotta K *et al* (2012) Second generation of pseudotype-based serum neutralization assay for Nipah virus antibodies: sensitive and high-throughput analysis utilizing secreted alkaline phosphatase. *J Virol Methods* **179**:226–232.
60. Kurup D, Wirblich C, Feldmann H, Marzi A, Schnell MJ (2015) Rhadovirus-based vaccine platforms against henipaviruses. *J Virol* **89**:144–154.
61. Lee KE, Umaphathi T, Tan CB, Tjia HTL, Chua TS, Oh HML *et al* (1999) The neurological manifestations of Nipah virus encephalitis, a novel paramyxovirus. *Ann Neurol* **46**:428–432.
62. Lehle C, Razafitrimo G, Razainirina J, Andriaholinirina N, Goodman SM, Faure C *et al* (2007) Henipavirus and Tioman virus antibodies in pteropodid bats, Madagascar. *Emerg Infect Dis* **13**:159–161.
63. Li M, Embury-Hyatt C, Weingartl HM (2010) Experimental inoculation study indicates swine as a potential host for Hendra virus. *Vet Res* **41**:33. doi: <http://dx.doi.org/10.1051/2Fvetres/2F2010005>
64. Li Y, Wang J, Hickey AC, Zhang Y, Li Y, Wu Y *et al* (2008) Antibodies to Nipah or Nipah-like viruses in bats, China. *Emerg Infect Dis* **14**:1974–1976.
65. Lim CC, Sitoh YY, Hui F, Lee KE, Ang BS, Lim E *et al* (2000) Nipah viral encephalitis or Japanese encephalitis? MR findings in a new zoonotic disease. *AJNR Am J Neuroradiol* **21**:455–461.
66. Lo MK, Bird BH, Chattopadhyay A, Drew CP, Martin BE, Coleman JD *et al* (2014) Single-dose replication-defective VSV-based Nipah virus vaccines provide protection from lethal challenge in Syrian hamsters. *Antiviral Res* **101**:26–29.
67. Luby SP, Gurley ES, Hossain MJ (2009) Transmission of human infection with Nipah virus. *Clin Infect Dis* **49**:1743–1748.
68. Luby SP, Hossain MJ, Gurley ES, Ahmed BN, Banu S, Khan SU *et al* (2009) Recurrent zoonotic transmission of Nipah virus into humans, Bangladesh, 2001–2007. *Emerg Infect Dis* **15**:1229–1235.
69. Mahalingam S, Herrero LJ, Playford EG, Spann K, Herring B, Rolph MS *et al* (2012) Hendra virus: an emerging paramyxovirus in Australia. *Lancet Infect Dis* **12**:799–807.

70. Marrianeau P, Guillaume V, Wong KT, Badmanathan M, Looi RY, Murri S *et al* (2010) Primate model for the emergent Nipah virus infection. *Emerg Infect Dis* **16**:507–510.
71. Marsh GA, de Jong C, Barr JA, Tachedjian M, Smith C, Middleton D *et al* (2012) Cedar virus: a novel henipavirus isolated from Australian bats. *PLoS Pathog* **8**:e1002836.
72. Mathieu C, Guillaume V, Sabine A, Ong KC, Wong KT, Legras-Lachuer C, Horvat B (2012) Lethal Nipah virus infection induces rapid overexpression of CXCL10. *PLoS ONE* **7**:e32157.
73. Middleton D, Westbury HA, Morrissy CJ, van der Heide BM, Russell GM, Braun MA, Hyatt AD (2002) Experimental Nipah virus infection in pigs and cats. *J Comp Pathol* **126**:124–136.
74. Middleton DJ, Morrissy CJ, van der Heide BM, Russell GM, Braun MA, Westbury HA *et al* (2007) Experimental Nipah virus infection in pteropid bats (*Pteropus poliocephalus*). *J Comp Pathol* **136**:266–272.
75. Middleton DJ, Weingartl HM (2012) Henipavirus in thier natural animal hosts. *Curr Top Microbiol Immunol* **359**:105–121.
76. Mills JN, Alim ANM, Bunning ML, Lee OB, Wagoner KD, Amman BR *et al* (2009) Nipah virus infection in dogs, Malaysia, 1999. *Emerg Infect Dis* **15**:950–952.
77. Mire CE, Versteeg KM, Cross RW, Agans KN, Fenton KA, Whitt MA, Geisbert TW (2013) Single injection recombinant vesicular stomatitis virus vaccines protect ferrets against lethal Nipah virus disease. *Virology* **10**:353. doi:10.1186/1743-422X-10-353.
78. Mounts AW, Kaur H, Parashar UD, Ksiazek TG, Cannon D, Arokiasamy JT *et al* (2001) A cohort study of health care workers to assess nosocomial transmissibility of Nipah virus, Malaysia, 1999. *J Infect Dis* **183**:810–813.
79. Mungall BA, Middleton D, Cramer G, Bingham J, Halpin K, Russell G *et al* (2006) Feline model of acute Nipah virus infection and protection with a soluble glycoprotein-based subunit vaccine. *J Virol* **80**:12293–12302.
80. Munster VJ, Prescott JB, Bushmaker T, Long D, Rosenke R, Thomas T *et al* (2012) Rapid Nipah virus entry into the central nervous system of hamsters via the olfactory route. *Sci Rep* **2**:736. doi: 10.1038/srep00736.
81. Murray K, Selleck P, Hooper P, Hyatt A, Gould A, Gleeson L *et al* (1995) A morbillivirus that caused fatal disease in horses and humans. *Science* **268**:94–97.
82. Negrete OA, Levrony EL, Aguilar HC, Betolotti-Ciarlet A, Nazarian R, Tajyar S, Lee B (2005) Ephrin B2 is the entry receptor for Nipah virus, an emergent deadly paramyxovirus. *Nature* **436**:401–405.
83. Ng BY, Lim CC, Yeoh A, Lee WL (2004) Neuropsychiatric sequelae of Nipah virus encephalitis. *J Neuropsychiatry Clin Neurosc* **16**:500–504.
84. Olson JG, Rupprecht C, Rollin PE, An US, Niezgoda M, Clemins T *et al* (2002) Antibodies to Nipah-like virus in bats (*Pteropus lylei*), Cambodia. *Emerg Infect Dis* **8**:987–988.
85. O'Sullivan JD, Allworth AM, Paterson DL, Snow TM, Boots R, Gleeson LJ *et al* (1997) Fatal encephalitis due to novel paramyxovirus transmitted from horses. *Lancet* **349**:93–95.
86. Pallister J, Middleton D, Cramer G, Yamada M, Klein R, Hancock TJ *et al* (2009) Chloroquine administration does not prevent Nipah virus infection and disease in ferrets. *J Virol* **83**:11979–11982.
87. Pallister J, Middleton D, Wang LF, Klein R, Haining J, Robinson R *et al* (2011) A recombinant Hendra virus G glycoprotein-based subunit vaccine protects ferrets from lethal Hendra virus challenge. *Vaccine* **29**:5623–5630.
88. Parashar UD, Sunn LM, Ong F, Mounts AW, Arif MT, Ksiazek TG *et al* (2000) Case-control study of risk factors for human infection with the new zoonotic paramyxovirus, Nipah virus, during a 1998–1999 outbreak of severe encephalitis in Malaysia. *J Infect Dis* **181**:1755–1759.
89. Paton NI, Leo YS, Zaki SR, Auchus AP, Lee KE, Ling AE *et al* (1999) Outbreak of Nipah-virus infection among abattoir workers in Singapore. *Lancet* **354**:1253–1256.
90. Pernet O, Schneider BS, Beaty SM, LeBreton M, Yun TE, Park A *et al* (2014) Evidence of henipavirus spillover into human populations in Africa. *Nat Commun* **5**:5342. doi: 10.1038/ncomms6342.
91. Pernet O, Wang YE, Lee B (2012) Henipavirus receptor usage and tropism. *Curr Top Microbiol Immunol* **359**:59–78.
92. Playford EG, McCall B, Smith G, Slinko V, Allen G, Smith I *et al* (2010) Human Hendra virus encephalitis associated with equine outbreak, Australia, 2008. *Emerg Infect Dis* **16**:219–223.
93. Ploquin A, Szecsi J, Matthieu C, Guillaume V, Barateau V, Ong KC *et al* (2013) Protection against henipavirus infection by use of recombinant adeno-associated virus-vector vaccines. *J Infect Dis* **207**:469–478.
94. Porotto M, Orefice G, Yokoyama CC, Mungall BA, Realubit R, Sganga ML *et al* (2009) Simulating henipavirus multicycle replication in a screening assay leads to identification of a promising candidate for therapy. *J Virol* **83**:5148–5155.
95. Premalatha GD, Lye MS, Arokiasamy J, Parashar U, Rahmat R, Lee BY, Ksiazek TG (2000) Assessment of Nipah virus transmission among pork sellers in Seremban, Malaysia. *Southeast Asian J Trop Med Public Health* **31**:307–309.
96. Prescott J, DeBuysscher BL, Feldmann F, Gardner DJ, Haddock E (2015) Single-dose live-attenuated vesicular stomatitis virus-based vaccine protects African green monkeys from Nipah virus disease. *Vaccine* **33**:2823–2829.
97. ProMED-mail (2013) Hendra virus, equine—Australia (09): (NS) dog affected. Archive number 20130721.1837123.
98. ProMED-mail (2015) Nipah encephalitis, human—Bangladesh (02). Archived number 20150407.3280088.
99. Quddus R, Alam S, Majumdar MA, Anwar S, Khan MR, Zahid Mahmud Khan AKS *et al* (2004) A report of 4 patients with Nipah encephalitis from Rajbari district, Bangladesh in the January 2004 outbreak. *Neurol Asia* **9**:33–37.
100. Rahman SA, Hassan SS, Olival KJ, Mohamed M, Chang LY, Saad NM *et al* (2010) Characterization of Nipah virus from naturally infected *Pteropus vampyrus* bats, Malaysia. *Emerg Infect Dis* **16**:1990–1993.
101. Ramasundram V, Tan CT, Chua KB, Chong HT, Goh KJ, Chew NK *et al* (2000) Kinetics of IgM and IgG seroconversion in Nipah virus infection. *Neurol J Southeast Asia* **5**:23–28.
102. Reynes JM, Counor D, Ong S, Faure C, Seng V, Molia S *et al* (2005) Nipah virus in Lyle's flying foxes, Cambodia. *Emerg Infect Dis* **11**:1042–1046.
103. Richmond R (2012) The Hendra vaccine has arrived. *Aust Vet J* **90**:N2.
104. Rockx B, Bossart KN, Feldman F, Geisbert JB, Hickey AC, Brining D *et al* (2010) A novel model of lethal Hendra virus infection in African green monkeys and the effectiveness of Ribavirin treatment. *J Virol* **84**:9831–9839.
105. Rockx B, Brining D, Kramer J, Callison J, Ebihara H, Mansfield K, Feldmann H (2011) Clinical outcome of henipavirus infection in hamsters is determined by the route and dose of infection. *J Virol* **85**:7658–7671.
106. Sahani M, Parashar U, Ali R, Das P, Lye MS, Isa MM *et al* (2001) Nipah virus infection among abattoir workers in Malaysia, 1998–1999. *Int J Epidemiol* **30**:1017–1020.



107. Sarji SA, Abdullah BJJ, Goh KJ, Tan CT, Wong KT (2000) Magnetic resonance imaging features of Nipah encephalitis. *AJR Am J Roentgenol* **175**:437–442.
108. Sejvar JJ, Hossain J, Saha SK, Gurley ES, Banu S, Hamadani JD *et al* (2007) Long term neurological and functional outcome in Nipah virus infection. *Ann Neurol* **62**:235–242.
109. Selvey LA, Wells RM, McCormack JG, Ansford AJ, Murray K, Rogers RJ *et al* (1995) Infection of humans and horses by a newly described morbillivirus. *Med J Aust* **162**:642–645.
110. Sendow I, Ratnawati A, Taylor T, Adjid RMA, Saepulloh M, Barr J *et al* (2013) Nipah virus in the fruit bat pteropus vampyrus in Sumatera, Indonesia. *PLoS ONE* **8**:e69544.
111. Smith I, Broos A, de Jong C, Zeddeman A, Smith C, Smith G *et al* (2011) Identifying Hendra virus diversity in pteropid bats. *PLoS ONE* **6**:e25275.
112. Smith I, Wang LF (2013) Bats and their virome: an important source of emerging viruses capable of infection humans. *Curr Opin Virol* **3**:84–91.
113. Tamin A, Harcourt BH, Lo MK, Roth JA, Wolf MC, Lee B *et al* (2009) Development of a neutralization assay for Nipah virus using pseudotype particles. *J Virol Methods* **160**: 1–6.
114. Tan CT, Goh KJ, Wong KT, Sarji SA, Chua KB, Chew NK *et al* (2002) Relapsed and late-onset Nipah encephalitis. *Ann Neurol* **51**:703–708.
115. Tan CT, Tan KS (2001) Nosocomial transmissibility of Nipah virus. *J Infect Dis* **184**:1367.
116. Tan CT, Wong KT (2003) Nipah encephalitis outbreak in Malaysia. *Ann Acad Med Singapore* **32**:112–117.
117. Tan KS, Sarji SA, Tan CT, Abdullah BJ, Chong HT, Thayaparan T, Koh CN (2000) Patients with asymptomatic Nipah virus infection may have abnormal cerebral MR imaging. *Neurol J Southeast Asia* **5**:69–73.
118. Tanimura N, Imada T, Kashiwazaki Y, Sharifah SH (2006) Distribution of viral antigens and development of lesions in chicken embryos inoculated with Nipah virus. *J Comp Pathol* **135**:74–82.
119. Torres-Velez FJ, Shieh WJ, Rollin PE, Morken T, Brown C, Ksiazek TG, Zaki SR (2008) Histopathologic and immunohistochemical characterization of Nipah virus infection in the guinea pig. *Vet Pathol* **45**:576–585.
120. Wacharapluesadee S, Lumlertdache B, Boongird K, Wanghongsa S, Chanhom L, Rollin P *et al* (2005) Bat Nipah virus, Thailand. *Emerg Infect Dis* **11**:1949–1951.
121. Walpita P, Barr J, Sherman M, Basler CF, Wang LF (2011) Vaccine potential of Nipah virus-like particles. *PLoS ONE* **6**:e18437.
122. Wang LF, Daniels P (2012) Diagnosis of henipavirus infection: current capabilities and future directions. *Curr Top Microbiol Immunol* **359**:179–196.
123. Wang LF, Harcourt BH, Yu M, Tamin A, Rota PA, Bellini WJ, Eaton BT (2001) Molecular biology of Hendra and Nipah viruses. *Microbes Infect* **3**:279–287.
124. Weingartl H, Czup S, Copps J, Berhane Y, Middleton D, Marszal P *et al* (2005) Invasion of the central nervous system in a porcine host by Nipah virus. *J Virol* **79**:7528–7534.
125. Weingartl HM, Berhane Y, Caswell JL, Loosmore S, Audonnet J-C, Roth JA, Czup M (2006) Recombinant Nipah virus vaccines protect pigs against challenge. *J Virol* **80**:7929–7938.
126. Weingartl HM, Berhane Y, Czup M (2009) Animal models of henipavirus infection: a review. *Vet J* **181**:211–220.
127. Williamson M, Hooper P, Selleck P, Gleeson LJ, Daniels PW, Westbury HA, Murray PK (1998) Transmission studies of Hendra virus (equine morbillivirus) in fruit bats, horses and cats. *Aust Vet J* **76**:813–818.
128. Williamson MM, Hooper PT, Selleck PW, Westbury HA, Slocombe RF (2000) Experimental Hendra virus infection in pregnant guinea-pigs and fruit bats (*Pteropus poliocephalus*). *J Comp Pathol* **122**:201–207.
129. Wong KT (2000) Emerging and re-emerging epidemic encephalitis: a tale of two viruses. *Neuropathol Appl Neurobiol* **26**:313–318.
130. Wong KT (2010) Emerging epidemic viral encephalitis with a special focus on henipaviruses. *Acta Neuropathol* **120**:317–325.
131. Wong KT (2010) Nipah and Hendra viruses: recent advances in pathogenesis. *Future Virol* **5**:129–131.
132. Wong KT, Grosjean I, Brisson C, Blanquiere B, Fevre-Montange M, Bernard A *et al* (2003) A golden hamster model for human acute Nipah virus infection. *Am J Pathol* **163**:2127–2137.
133. Wong KT, Ong KC (2011) Pathology of acute henipavirus infection in humans and animals. *Patholog Res Int* **2011**:Article ID 567248. doi: 10.4061/2011/567248.
134. Wong KT, Robertson T, Ong BB, Chong JW, Yaiw KC, Wang LF *et al* (2009) Human Hendra virus infection causes acute and relapsing encephalitis. *Neuropathol Appl Neurobiol* **35**:296–305.
135. Wong KT, Shieh W-J, Zaki SR, Tan CT (2002) Nipah virus infection, an emerging paramyxoviral zoonosis. *Springer Semin Immunopathol* **24**:215–228.
136. Wong KT, Shieh WJ, Kumar S, Norain K, Abdullah W, Guarner J *et al* (2002) Nipah virus infection: pathology and pathogenesis of an emerging paramyxoviral zoonosis. *Am J Pathol* **161**:2153–2167.
137. Wong KT, Tan CT (2012) Clinical and pathological manifestations of human henipavirus infection. *Curr Top Microbiol Immunol* **359**:95–104.
138. Wong S, Lau S, Woo P, Yuen KY (2007) Bats as continuing source of emerging infections in humans. *Rev Med Virol* **17**:67–91.
139. Wright PJ, Cramer G, Eaton BT (2005) RNA synthesis during infection by Hendra virus: an examination by quantitative real-time PCR of RNA accumulation, the effect of ribavirin and the attenuation of transcription. *Arch Virol* **150**:521–532.
140. Wu Z, Yang L, Yang F, Ren X, Jiang J, Dong J *et al* (2014) Novel henipa-like virus, Mojiang paramyxovirus, in rats, China, 2012. *Emerg Infect Dis* **20**:1064–1066.
141. Yoneda M, Georges-Courbot MC, Ikeda F, Ishii M, Nagata N, Jacquot F *et al* (2013) Recombinant measles virus vaccine expressing the Nipah virus glycoprotein protects against lethal Nipah virus challenge. *PLoS ONE* **8**:e58414.
142. Yoneda M, Guillaume V, Ikeda F, Sakuma Y, Sato H, Wild TF, Kai C (2006) Establishment of a Nipah virus rescue system. *Proc Natl Acad Sci U S A* **103**:16508–16513.